

## CHAPTER 1

# Dental Treatment of Small Mammals – Development and Aims

Eighty to a hundred years ago, the majority of a veterinary surgeon's dental patients were horses. They were primarily used as working animals and thus needed a healthy dentition. In the decades that followed, the number of dogs kept as pets rose significantly. Consequently, more dogs with dental conditions were presenting to general veterinary practices and to the increasing number of specialized small animal practices. From the 1970s on, the number of pet cats was also increasing, with a concomitant increase in the number of cats requiring dental treatment, particularly in urban areas. During the last 15 years, a focus of interest has been on small herbivorous mammals (rabbits, guinea pigs, chinchillas and degus) as pets.

Keeping small pets is becoming ever more popular, with lagomorphs and rodents in particular attracting attention as being “low-maintenance” animals – especially in urban areas. Nowadays, small pets comprise almost a quarter of patients in an urban veterinary practice, excluding those practices that focus only on small mammals. This is challenging for veterinarians, as they are presented with a great variety of animal species, and many of them must be treated in different ways due to their anatomical and physiological peculiarities. An ever-increasing knowledge in a variety of disciplines is required in order to make correct diagnoses and treat these patients appropriately. This is especially true in the area of odontology, as many small mammals have dental ailments.

One of the reasons for the high number of dental ailments presenting in small mammals is that some pet owners have an insufficient understanding of the dietary requirements of their herbivorous pets, which can lead to dental overgrowth with all of its possible

consequences. This problem is compounded by the fact that for each species there is a vast multitude of foods available in specialist shops. In principle (and often contrary to the labeling), many of these are not suitable when given as a complete diet. The variety of feeds on offer is difficult to choose from for a pet owner who is not well informed. Consequently, the owner will often feed these pets – more or less randomly and uncritically – whatever seems suitable to them and whatever the animal prefers to eat. These kinds of high-energy grain mixtures often lead to gastrointestinal diseases, as well as resulting in insufficient abrasion of the incisors and cheek teeth, which keep growing during the whole lifetime of the animal. This will inevitably result in an acquired malocclusion.

Gastrointestinal disease tends to be readily recognized by the pet owner due to fairly obvious symptoms such as diarrhoea, abdominal pain or constipation. In contrast, dental problems may go unnoticed in their early stages by an animal's owner. Most animals that are starting to develop malocclusions continue to eat enough, although they may already be suffering from painful changes in their teeth and jaws. Their general condition may appear well, they may be lively, continue to groom and exhibit an interest in their surroundings, their owners or their conspecifics. Any weight loss may not be noticed early on unless the animal is regularly weighed. Early symptoms of malocclusion are also difficult to detect when the animals are kept in a group. For example, in the early stages of a dental disorder, many patients start to eat selectively, i.e. they prefer soft feeds and avoid harder feeds like hay. Such behavior may go unnoticed in animal groups. For these reasons, many patients do not present for treatment until they suffer



**Figure 1.1** Abscess of the mandible as a result of chronic apical periodontitis of the first lower cheek tooth (P4) in a four-year-old guinea pig.

from quite advanced malocclusions or the formation of a tooth-associated jaw abscess which is clearly visible (Figure 1.1). Radiographs showing the extent of osseous changes that are already present are often met with amazement. How could the animals hide these painful conditions for such a long time?

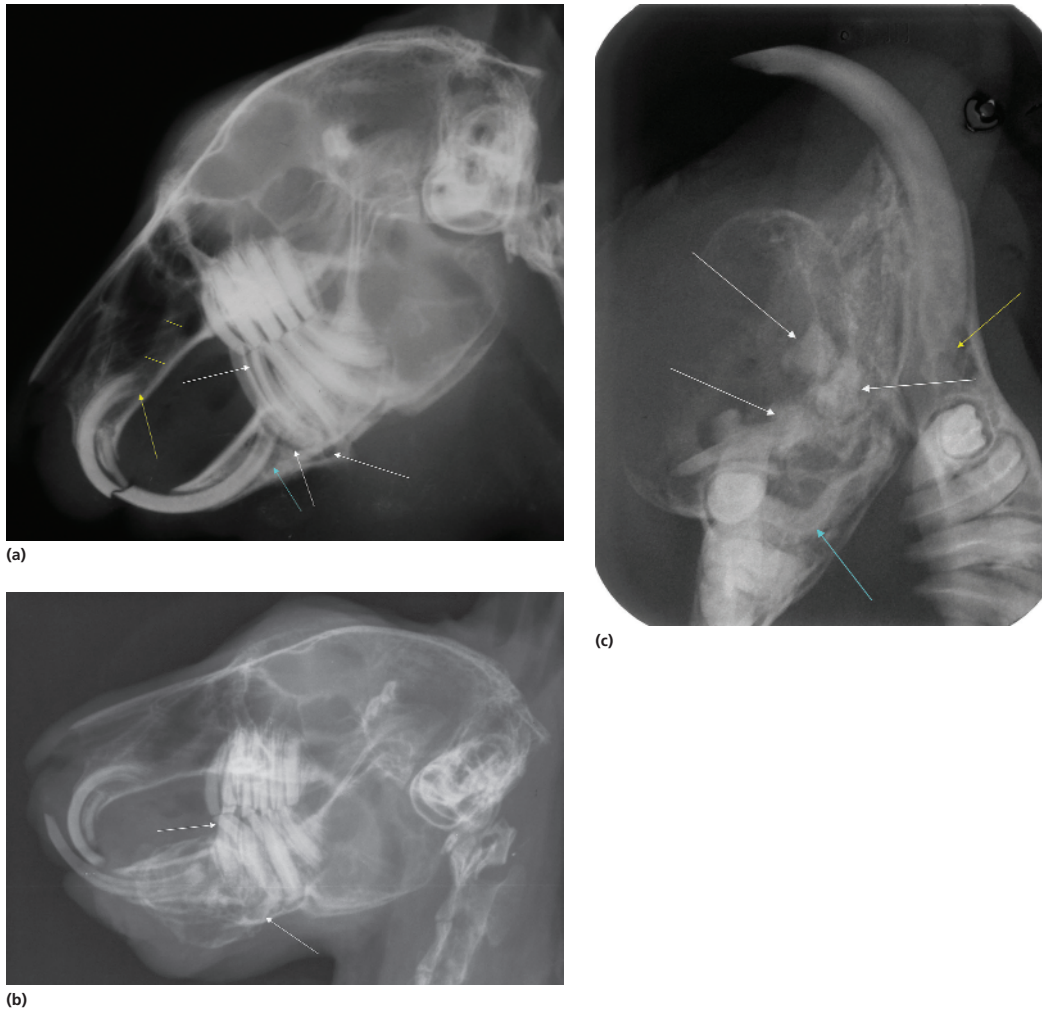
In order to prevent situations like these arising, veterinarians should take every opportunity to describe early symptoms of dental disorders to an animal's owner and give advice about species-appropriate feeding and husbandry. Such opportunities include routine examinations, annual vaccinations, visits for neutering, clipping of claws and treatments for ecto- and endoparasitic diseases. Additionally, prophylactic dental examinations are generally recommended. The earlier malocclusions are detected, the better are the chances of curing them

with specific therapies, or at least having a positive impact on the course of the disease.

During the last three decades, not only has the way that corrections of the dental problems are performed changed but also the aims of these corrections. In the 1970s and 1980s, lagomorphs and herbivorous rodents with malocclusions would simply have had their elongated incisors clipped, and tips of teeth or spikes and spurs of the molars removed with a fine Luer bone rongeur forceps. Finally, the occlusal surface of the molars would have been "filed" a little. Little attention was given to the etiology of dental disorders, the anatomical and pathological peculiarities of the dentition of different species or to a possible prophylaxis of dental changes. In addition, there were no adequate instruments suitable to use for closer diagnostic examinations or therapies. Furthermore, radiographs of the head were generally taken in only one or two views, and almost always just for jaw abscesses, but not for so-called "uncomplicated" dental treatments. During recent years, dramatic changes have occurred concerning all of the aforementioned, and these changes require a re-definition of the aims of an optimal dental treatment.

Nowadays, the aim of correcting an occlusion involves more than re-establishing the best possible intraoral occlusion by simple trimming of the incisors and molars. Dental therapies are now looking to establish the primary causes of disorders of the jaw and teeth. If the cause of a disorder can be determined using adequate diagnostics (e.g. history taking, clinical and intraoral examinations, radiographic examination using a variety of positionings, etc.), it may then be possible to rectify it by means of a specific therapy. Often, a long-term cure may be feasible. Even if it is not possible to rectify the condition, then a treatment specific to the individual situation may at least delay progress of the pathological changes.

However, if diagnostics and therapy are limited to pathological changes that can be seen intraorally, as they were in the past, then hidden intraosseous processes will continue to progress unrestrictedly. One may sometimes wonder why a treatment has not been successful despite the correction of the dentition having been performed precisely according to the intraoral findings, not realizing that the pain is caused by intra-alveolar changes. A typical example of this is shown in Figure 1.2. This rabbit has an abscess of the lower jaw. Its cause is a longitudinally split lower mandibular cheek tooth (P3), with apical inflammation. A subtle



**Figure 1.2** Abscess of the mandible in a three-year-old rabbit. (a) On a laterolateral radiographic view, periapical periodontitis and a longitudinal split of the first lower cheek tooth (P3; white arrows) can be seen. A slight distension of the ventral mandibular cortical bone with swelling of soft tissue is also clearly visible. Retrograde displacement of the apex of the lower incisor with periapical osteolysis (turquoise arrow), secondary malocclusion of the incisor with dental overgrowth and abnormal, blunt contact surface of the mandibular incisor as well as retrograde displacement of the maxillary incisor (yellow arrow) are also recognizable. The nasolacrimal duct is dilated (yellow lines). (b) Eight months after a simple abscess-related incision without tooth extraction, the laterolateral view shows a pronounced abscess of the mandible with a markedly distended, bony abscess capsule. A mandibular cheek tooth (P3) and a mandibular incisor are missing. The second lower cheek tooth (P4) is severely deformed intra-alveolar as well as extra-alveolar (white arrows). The clinical crown of the remaining mandibular incisor is markedly elongated (prognathic tooth position) and there are manifestations of apical inflammation. The maxillary incisors are elongated. (c) The intraoral radiographic image of the mandibles shows that the right incisor is missing and the adjacent first cheek tooth (P3) is only recognizable as an unstructured, multipart dentinoid (white arrows). There is a strong intra-alveolar deviation of the following second cheek tooth (P4; turquoise arrows) as well as extra-alveolar overgrowth and apical periodontitis of the left incisor (yellow arrow). The socket of the first left cheek tooth (P3) is slightly expanded.

overgrowth of the affected premolar dominates intra-orally. Secondly, the infection has spread to the adjacent incisor. Unless the whole problem is identified

correctly and both teeth causing it are extracted, the initially local infection will spread, leading to an area of lesion that is “inexplicably” not improving.

Misdiagnoses like these, as well as other complications, can be avoided by the use of well-founded radiographic diagnostics, and thus the majority of tooth and jaw diseases can now be treated more specifically and effectively. This should be our primary aim, in conjunction with an optimal correction of the dentition and providing the owners of small mammals with advice concerning diet and care of these animals. Diagnostics and therapy of tooth and jaw diseases in lagomorphs and rodents are highly complex and sometimes complicated areas of expertise. This, along with the variability and uniqueness of each individual case, makes this a fascinating area of work, one in which we face new challenges every day, with a variety of interesting problems to solve and decisions to make.

The relatively high frequency of malocclusions in these animal species is reflected in the scientific literature.

A multitude of publications on this problem has appeared over the last few years. However, guinea pigs are largely omitted in the literature from English-speaking countries, despite being common pets in these countries. In addition to the literature, veterinarians who wish to expand their knowledge in theory as well as in practice may choose from a wide range of national and international advanced training courses. Concurrently, new instruments are being developed that are particularly suitable for dental treatment of pets. It is also possible to use teleconsulting via the internet, for example, when looking for help in interpreting X-ray images (e.g. [www.curoxray.de](http://www.curoxray.de)). Given all these resources, one would hope that there will be no more insufficient diagnoses (e.g. diagnoses being made without radiographic examinations of the skull) or inappropriate therapies of malocclusions in small pets.